

IMMOBILISATION OF PARTIALLY EDENTULOUS MANDIBULAR FRACTURE WITH A REMOVABLE DENTAL PROSTHESIS

KISMİ EDENTİLÖZ HASTADA MANDİBULA FRAKTÜRÜNÜN HAREKETLİ DİŞ PROTEZİ İLE SABİTLENMESİ

Hakan Bulam, Kemal Fındıkçioğlu, Selahattin Özmen

Gazi Üniversitesi Tıp Fakültesi, Plastik, Rekonstrüktif ve Estetik Cerrahi Anabilim Dalı, ANKARA

Dear Editor;

Dentoalveolar fractures are very common facial fractures especially in childhood. Most common etiologic factors are falling, sport activities and traffic accidents. Stabilization of dentoalveolar fractures can be performed with arch bar, screws, wires and fiber-splints.^{1,2} Geriatric population consist of 2-3% of total dentoalveolar fracture patients. It is a challenge to manage the dentoalveolar fractures in these partially edentulous patients because interdental wire stabilization or fiber-splints cannot be used.^{3,4} We aimed to introduce an alternative method that can be used to stabilize dentoalveolar fractures in partially edentulous patients.

Case Report

A Sixty-two-years-old female patient admitted to emergency department with facial trauma after a traffic accident. She had gingival edema and abrasions on right side of lower lip but no any open wound. She was partially edentulous. She had only 3 teeth on the mandible: right canine, left canine and left 1st premolar. Right canine was mobile with the alveolar bone underneath (Figure 1). Fragmented dentoalveolar segment was only attached to lingual and buccal mucosa. Dentoalveolar fracture was detected in Maxillofacial CT (Figure 2). It was impossible to stabilize the fracture segment with interdental wires or splints. She already had a removable dental prosthesis with 3 spaces for persistent teeth and this dental prosthesis was not broken with trauma by chance. We thought that this prosthesis was a good candidate to fix the fracture. The fracture was reduced under inferior alveolar nerve block and dental prosthesis was inserted. Fracture was immobilized with the help of fixed right canine that was over the fractured alveolar segment. Immobilization was achieved without any complication. We suggested chin-cap and soft diet for 4 weeks. Fracture segment was immobile four weeks later.

Immobilization with previously used dental prosthesis can be used as an alternative, easy, quick and cost-effective method to stabilize dentoalveolar fractures in partially edentulous patients.

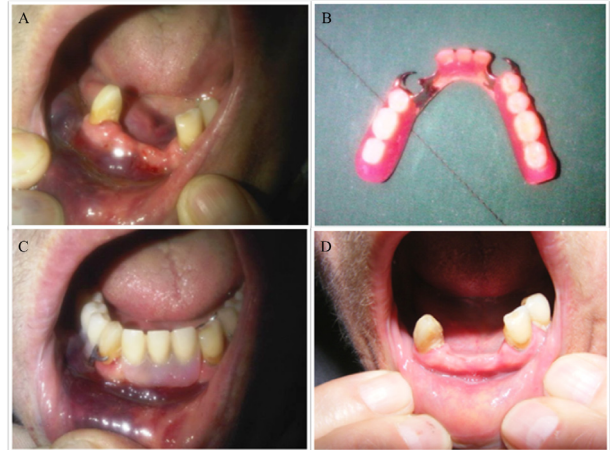

Figure 1. Preoperative view of the patient and removable dental prosthesis

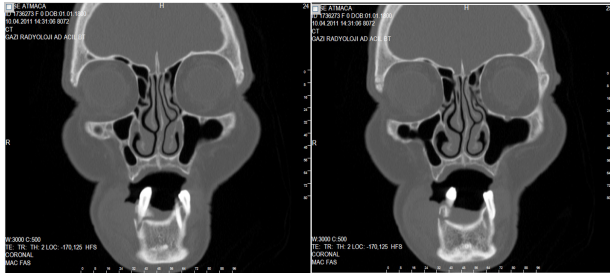


Figure 2. Maxillofacial CT

Dr. Hakan BULAM

Gazi Üniversitesi Tıp Fakültesi,
Plastik Rekonstrüktif ve Estetik Cerrahi AD, Ankara
E-mail: hakanbulam@hotmail.com

REFERENCES

1. Gibbons AJ. Bone screw stabilization of a dentoalveolar fracture. *J Oral Maxillofac Surg.* 2007;65(7):1439.
2. Baliga M, Shenoy V, Krishna L. Quick technique for immobilisation of dentoalveolar fracture. *Br J Oral Maxillofac Surg.* 2003;41(6):417.
3. Tuli T, Hächl O, Rasse M, Kloss F, Gassner R. Dentoalveolar trauma. Analysis of 4763 patients with 6237 injuries in 10 years. *Mund Kiefer Gesichtschir.* 2005;9(5):324-9.
4. Ellis E III, Price C. Treatment protocol for fractures of the atrophic mandible. *J Oral Maxillofac Surg* 2008;66:421–35.