

## A BLADE ALTERNATIVE FOR NARROW AREA SURGIRIES: STAB KNIFE

### ÖZELLİKLİ CERRAHİ ALANLARDA ALTERNATİF BİR BİSTÜRİ: STAB BIÇAĞI

Ufuk Askeroğlu, Seda Asfuroğlu Barutca, Özay Özkaya, İlker Üsçetin, Mithat Akan

Okmeydanı Eğitim ve Araştırma Hastanesi, Plastik Rekonstrüktif ve Estetik Cerrahi Kliniği, İSTANBUL

#### Dear Editor;

Cleft lip and hypospadias surgeries, in which most of the patients are infants, are difficult and surgical experience requiring procedures. Careful incisions and flap elevation are crucial for the success of the surgery. Because of the surgical area is narrow and restricted to the movements, blade choice and usage are the main discussions about these operations. Although many different instruments such as number 11 blade, number 15 blade and electrocautery have been successfully used in cleft lip and hypospadias operations none of them were suitable enough for incision and dissection. There are few types of angled blades including trapezoid knife, clear corneal knife and stab knife which are also being used by ophthalmologists. According to the literature review, clear corneal knife previously used for incisions at cleft palate surgery and fistula closure with its advantage of being angled between cutting edge and handle and also having two cutting edge.<sup>1</sup> Those advantages also simplify dissection of the palatal muscles during intravelar veloplasty.

Stab knife which has an angle (30 degree) between cutting edge and the upper non-cutting margin, can be suggested for narrow area surgeries similarly (Figure 1). In current practice this blade is being used to make incisions at the corneoscleral junction in cataract surgery by ophthalmologists.<sup>2</sup> Stab knife which has one cutting edge is serves an excellent incision and dissection of the lip flaps and muscles and also in hypospadias surgery (Figure 2). Because stab knife has one cutting edge, dissection can be limited in one direction to avoid any injury to surrounding tissues as opposed to the two cutting edges of the angled blades, which requires a sawing motion for cutting. Because it has not a pointed tip, a safe dissection can be provided by avoiding "feathering" or "button holing" of fine tissue layers.<sup>3,4</sup> This blade simplifies incision with being small in the narrow surgical area. Furthermore, nowadays considering small animals like rats are being the most popular

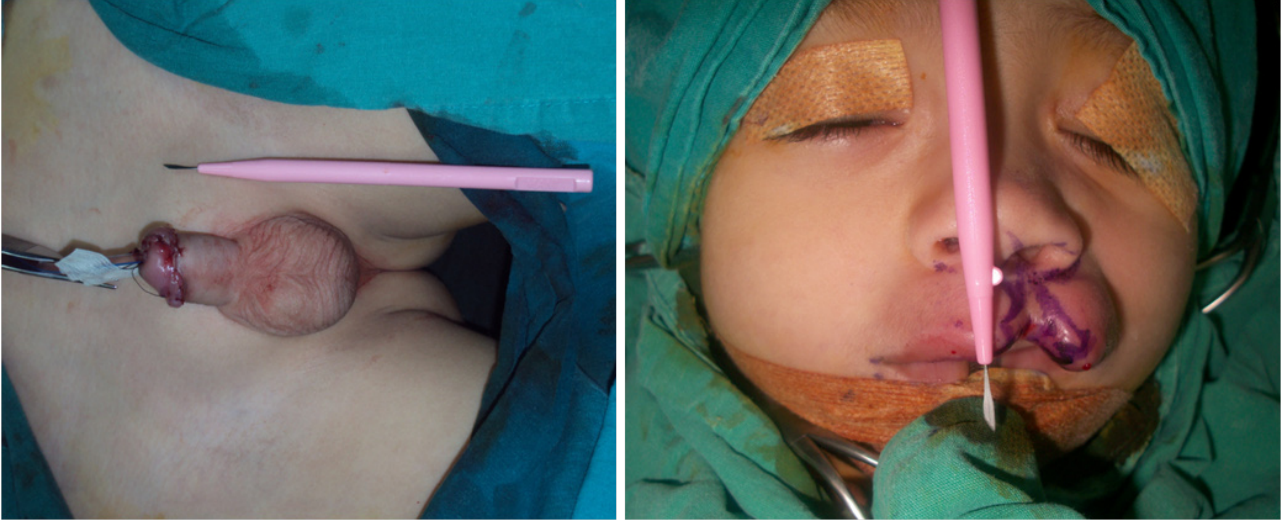experimental animals, it can be emphasized that corneal blade is more appropriate than 15 blade with its easiness for operating small body surfaces (Figure 3).

Another advantage of this blade is its handle differences from conventional blades. Conventional blade handles are thick, unbalanced and do not have the proper "feel" in small areas. This is not the best design for an instrument, which we use to create a very delicate incision in infants lips or penis. Stab Knife has an ergonomic handle, which more closely approximates a fine writing instrument, offering the surgeon superior control in creating the incision and also a dissection. It is also 11.5 cm in length which is easy to use and grasp in hand.

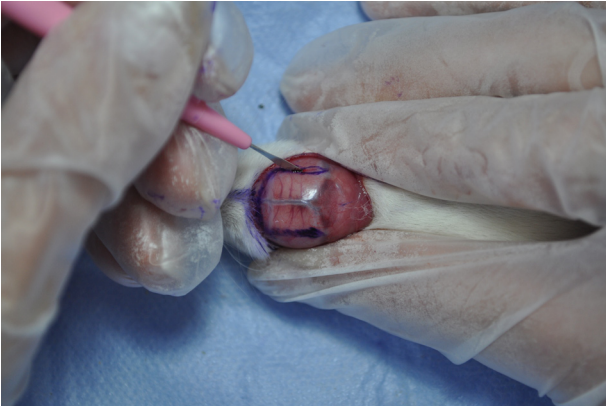The cost of this disposable knife is only about \$ 6 which gives a relatively competitive advantage across the other substitute blades. We think stab knife is a welcome addition to the fine instrumentation for cleft lip and hypospadias surgery.




Figure 1. Stab knife with one cutting edge



**Figure 2.** The knife serving an excellent incision and dissection in cleft lip and hipospadias surgery



**Figure 3.** The blade simplifying incision with being small in the narrow surgical area

### KAYNAKLAR

1. Sharma KR, Nanda V, Makkar SS. Angled Blade For Cleft Plate Surgery. *PlastReconstrSurg.* 2005;116:1572
2. Davis EA, Lindstrom RL. Techniques of tilt and tumblephacoemulsification. In *Cataract Surgery, Tecniqe, Complication, Management.* 2nd ed. Pennsylvania: SaundersElsevier 2004: 193-203
3. Vidyadharan R, Slator R. Angled blade for cleft palate surgery. *PlastReconstrSurg.* 2006 ;118:810.
4. Sharma RK, Nanda V, MakkarSS. Angled lamellar blade for cleft palate surgery. *PlastReconstrSurg.* 2007;119:428.

#### Dr. Ufuk ASKEROĞLU

Okmeydanı Eğitim ve Araştırma Hastanesi  
Plastik, Rekonstrüctif ve Esteti Cerrahi Kliniği, İstanbul  
E-posta: cagdasorman@gmail.com